고려대학교의료원
KOREA UNIVERSITY MEDICINE

Basic Principles of Management for Urethral Strictures

Min Gu Park, M.D., Ph.D.

Department of Urology,
Korea University Anam Hospital, Seoul, Korea

ENABLING
FUTURE MEDICINE

고려대학교의료원
KOREA UNIVERSITY MEDICINE

EAU Guidelines on Urethral Strictures

N. Lumen (Chair), F. Campos-Juanatey,
K. Dimitropoulos, T. Greenwell, F.E. Martins, N. Osman,
A. Ploumidis, S. Riechardt, M. Waterloos
Guidelines Associates: R. Barratt, G. Chan,
F. Esperto, W. Verla
Guidelines Office: R. Shepherd

Management for Urethral Strictures

Recommendations	Strength rating
Do not intervene in patients with **asymptomatic incidental (>16Fr) stricture.**	Weak
Consider long-term suprapubic catheter in patients with radiation-induced bulbomembranous strictures and/or poor performance status.	Weak

Summary of evidence	LE
Patients with **asymptomatic incidental (> 16 Fr) strictures** have a low risk of progression and to develop symptoms.	3
Only half of the patients initially treated with a suprapubic catheter for **radiation-induced bulbomembranous strictures** will proceed with urethroplasty.	3

- Surgeons may offer urethral dilation, direct visual internal urethrotomy, or urethroplasty for the initial treatment of a short (<2cm) bulbar urethral stricture. (Conditional Recommendation; Evidence Level: Grade C)

  ✓Urethral dilation and direct visual internal urethrotomy have similar long-term outcomes in short strictures, with the highest success rates found in those with bulbar strictures <1cm.

Management for Urethral Strictures

Recommendations	Strength rating
Do not use DVIU for penile strictures.	**Strong**
Do not use DVIU/dilatation as solitary treatment for long (> 2 cm) segment strictures.	**Strong**
Perform DVIU/dilatation for a primary, single, short (< 2 cm) and non-obliterative stricture at the bulbar urethra.	Weak
Perform DVIU/dilatation for a short, veil-like recurrent stricture after prior bulbar urethroplasty.	Weak
Use either “hot” or “cold knife” techniques to perform DVIU depending on operator experience and resources.	Weak

Management for Urethral Strictures

Summary of evidence	LE
Direct vision internal urethrotomy (DVIU) performs poorly in penile strictures. DVIU at the penile urethra might provoke venous leakage from the corpora cavernosa with subsequent risk of erectile dysfunction.	**1b**
Increased stricture length is associated with higher risk of failure of DVIU.	**1b**
In selected patients with a primary, single, short (< 2 cm) and non-obliterative bulbar stricture, a five-year stricture-free rate of up to 77% can be expected in DVIU.	3
DVIU has a stricture-free rate of 51%, if performed for a short (<1cm) , veil-like recurrent stricture after prior bulbar urethroplasty.	3
There is conflicting evidence that "**hot knife**" (laser, bipolar) DVIU would be superior compared to "**cold knife**" DVIU after more than one year of follow-up.	**1a**

Management for Urethral Strictures

Recommendations	Strength rating
Use visually controlled dilatation in preference to blind dilatation.	Weak
Do not perform repetitive (> 2) **DVIU/dilatation**s if urethroplasty is a viable option.	**Strong**

Summary of evidence	LE
Visually controlled **dilatation** after endoscopic or fluoroscopic guidewire placement has a low complication rate.	3
Repetitive dilatations/direct vision internal urethrotomy have no long-term freedom of recurrence and increase stricture complexity.	**1b**

- Surgeons may safely remove the urethral catheter within 72 hours following uncomplicated dilation or direct visual internal urethrotomy. (Conditional Recommendation; Evidence Level: Grade C)

  ✓There is no evidence that leaving the catheter longer than 72 hours improves safety or outcome, and catheters may be removed after 24-72 hours.

    ➢Catheters may be left in longer for patient convenience or if in the surgeon's judgment early removal will increase the risk of complications.

Management for Urethral Strictures

- In patients who are not candidates for urethroplasty, clinicians may recommend self catheterization after direct visual internal urethrotomy to maintain temporary urethral patency. (Conditional Recommendation; Evidence Level: Grade C)
  - ✓ self-catheterization for greater than 4 months after DVIU reduced recurrence rates compared to performing self-catheterization for less than 3 months

Recommendations	Strength rating
Perform ISD to stabilize the stricture after dilatation/direct vision internal urethrotomy <u>if urethroplasty is not a viable option.</u>	Weak
Use intra-urethral corticosteroids in addition to ISD to stabilize the urethral stricture.	Weak

Summary of evidence	LE
Stricture recurrence was reduced in men performing **intermittent self-dilatation** (ISD) versus those who did not.	**1a**
Intra-urethral corticosteroids in addition to **ISD** delays the time to recurrence.	**1a**

Management for Urethral Strictures

Recommendation	Strength rating
Use intralesional injections only in the confines of a clinical trial.	Weak

Summary of evidence	LE
Intralesional injections (Steroids, Mitomycin C, Platelet rich plasma) after DVIU might improve stricture-free rates on the short-term compared to DVIU alone. Experience is limited and the use of these drugs are off-label. Significant uncertainty exists about drug, dose, volume and technique.	**1a**

Recommendation	Strength rating
Offer drug (paclitaxel)-coated balloon dilatation for a short (< 3 cm) bulbar stricture recurring after at least two prior endoscopic treatments, but only in patients for whom urethroplasty is not an option.	Weak

Summary of evidence	LE
Drug (paclitaxel)-coated balloon dilatation is associated with higher anatomic patency rates (at 6 month) and lower risk of retreatment (at one year) as compared to standard dilatation/DVIU in patients with short (< 3 cm), bulbar strictures that underwent at least two prior failed endoscopic treatments.	**1b**

Management for Urethral Strictures

Recommendations	Strength rating
Do not use permanent urethral stents.	**Strong**
Do not use urethral stents for penile strictures.	**Strong**
Use a temporary stent for recurrent bulbar strictures after direct vision internal urethrotomy to prolong time to next recurrence only if urethroplasty is not a viable option.	Weak

Summary of evidence	LE
Permanent urethral stents have a high complications and failure rate and make subsequent urethroplasty more challenging if they fail.	3
Stents have a higher failure rate in the penile urethra.	3
Temporary stents after DVIU (direct vision internal urethrotomy) /dilatation at the bulbar urethra prolong time to next recurrence compared to DVIU/dilatation alone.	**1b**

Management for Urethral Strictures

Anterior Urethral Reconstruction

- Surgeons may initially treat meatal or fossa navicularis strictures with either dilation or meatotomy. (Clinical Principle)
- Surgeons should offer urethroplasty to patients with recurrent meatal or fossa navicularis strictures. (Moderate Recommendation; Evidence Level: Grade C)

Summary of evidence	LE
Post-meatoplasty/urethroplasty patency rates in men with meatal stenosis or fossa navicularis/distal urethral strictures range between 57-100% depending on type of surgical intervention with high patient satisfaction and minimal complications.	3

Recommendation	Strength rating
Offer open meatoplasty or distal urethroplasty to patients with meatal stenosis or fossa navicularis/distal urethral strictures.	Weak

- Surgeons may place a suprapubic cystostomy to promote “urethral rest” prior to definitive urethroplasty in patients dependent on an indwelling urethral catheter or intermittent self-dilation. (Conditional Recommendation; Evidence Level: Grade C)

  - ✓Proper evaluation of a urethral stricture may require a period of “urethral rest,” without urethral instrumentation, to determine the true severity of the stricture including its degree of narrowing.

    - ➢Tissue recovery and stricture maturation can be expected in 4-6 weeks, which enables accurate radiographic and/or endoscopic identification in preparation for definitive management.

- Surgeons should offer urethroplasty to patients with penile urethral strictures given the expected high recurrence rates with endoscopic treatments. (Moderate Recommendation; Evidence Level: Grade C)

  - ✓Strictures involving the penile urethra are unlikely to respond to dilation or urethrotomy, and these patients should be offered urethroplasty at the time of diagnosis.

    - ➢Success rates of single stage urethroplasty using penile fasciocutaneous flaps and oral mucosal grafts appear similar regardless of technique used.

Management for Urethral Strictures

Recommendations [penile urethral strictures]	Strength rating
Offer men with penile urethral stricture disease **augmentation urethroplasty** by either a single-stage or staged approach taking into consideration previous interventions and stricture characteristics.	**Strong**
Offer an interval of at least 4 to 6 months before proceeding to the second stage of the procedure provided that outcome of the first stage is satisfactory.	Weak
Do not offer **anastomotic urethroplasty** to patients with penile strictures > 1 cm due to the risk of penile chordee post-operatively.	**Strong**
Counsel patients with penile strictures that single-stage procedures might be converted to staged ones in the face of adverse intra-operative findings.	**Strong**

Management for Urethral Strictures

Summary of evidence [penile urethral strictures]	LE
Stricture-free rates for **single-stage penile augmentation urethroplasties** range from 70%-100% for dorsal oral mucosa graft (OMG) augmentation, 67-100% for penile skin flap (PSF) augmentation, 55-92.6% for ventral OMG augmentation and 62-78% for dorsal skin graft (SG) augmentation. Overall stricture-free rates for staged OMG penile augmentation urethroplasties range from 70-100%.	2b
In staged urethroplasties, an interval of at least 4 to 6 months has been proposed before proceeding to the tubularization of the urethra, provided that the graft has healed uneventfully.	4
The use of **anastomotic urethroplasty** in the management of penile urethral stricture disease has been discouraged due to the risk of chordee post-operatively. Anastomotic urethroplasty can be offered in selected cases of very short (< 1 cm), injury-associated penile strictures.	3
In case of adverse intra-operative findings, a single-stage approach might not be feasible and must be converted into a staged approach.	3

Management for Urethral Strictures

Recommendations [“Short” bulbar strictures]	Strength rating
Use **tEPA** for short posttraumatic bulbar strictures with complete obliteration of the lumen and full thickness spongiofibrosis.	**Strong**
Use **ntEPA** or **free graft urethroplasty** instead of tEPA for short bulbar strictures not related to straddle injury.	Weak

**LE1b for comparison between tEPA and FGU and LE3 for tEPA versus ntEPA versus FGU*

Summary of evidence [“Short” bulbar strictures]	LE
For short post-traumatic strictures transecting excision and primary anastomosis (**tEPA**) has good patency rates.	3
For short bulbar strictures not related to straddle injury, tEPA, ntEPA and free graft urethroplasty (FGU) have the same patency rates, but ntEPA and FGU have less **erectile dysfunction** or penile complications than tEPA.	**1b**-3*

- Surgeons should use oral mucosa as the first choice when using grafts for urethroplasty. (Expert Opinion)
  - Surgeons may use either buccal or lingual mucosal grafts as equivalent alternatives. (Strong Recommendation; Evidence Level: Grade A)
  - Surgeons should not perform substitution urethroplasty with allograft, xenograft, or synthetic materials except under experimental protocols. (Expert Opinion)

Management for Urethral Strictures

Recommendations [“Longer” bulbar strictures]	Strength rating
Use free graft urethroplasty for bulbar strictures not amendable to excision and primary anastomosis (EPA).	**Strong**

Summary of evidence [“Longer” bulbar strictures]	LE
For strictures not amenable to EPA, FGU provides an 88-91% patency rate at short to medium follow-up	**1b**

Recommendation	Strength rating
Use dorsal, dorsal-lateral, or ventral approach according to surgical practice, expertise, and intra-operative findings.	**Strong**

Summary of evidence	LE
Location of the graft during urethroplasty for bulbar strictures has no impact on patency rates.	**1b**

Management for Urethral Strictures

Recommendation [recurrence after bulbar urethroplasty]	Strength rating
Use **oral mucosa free graft** urethroplasty for ReDo urethroplasty in case the of a long stricture.	**Strong**

Summary of evidence [recurrence after bulbar urethroplasty]	LE
Buccal mucosa free graft urethroplasty after failed urethroplasty achieves the same patency rates as primary cases.	3

Management for Urethral Strictures

Summary of evidence [Perineal urethrostomy]	LE
Perineal urethrostomy (PU) provides very good short- and long-term outcomes for men with complex urethral stricture disease.	**1a**
PU provides very good short and long-term outcomes for men who are unable to have complex reconstruction due to co-morbidities.	2b
Augmented Gil-Vernet-Blandy or "**7-flap**" PU yield very good outcomes in men with extension of their urethral stri cture disease into the proximal bulbar or membranous urethra.	2
"7-flap" PU yields very good results in obese men.	3

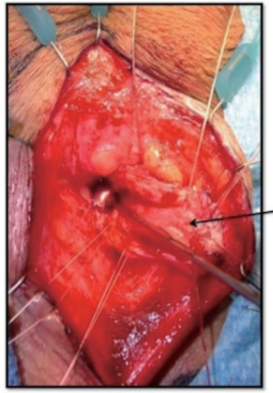

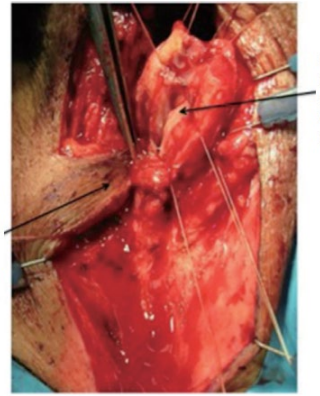

Management for Urethral Strictures

Recommendations	Strength rating
Offer **perineal urethrostomy (PU)** as a management option to men with complex anterior urethral stricture disease.	**Strong**
Offer PU for men with anterior urethral stricture disease who are not fit or not willing to undergo formal reconstruction.	Weak
Choose type of PU based on personal experience and patient characteristics.	Weak
Consider augmented Gil-Vernet-Blandy perineal urethrostomy or “7-flap” PU in men with proximal bulbar or membranous urethral stricture disease.	Weak
Consider “7-flap” urethroplasty in obese men.	Weak

- Bladder Neck Contracture/Vesicourethral Stenosis
  - Surgeons may perform a dilation, bladder neck incision, or transurethral resection for bladder neck contracture after endoscopic prostate procedure. (Expert Opinion)
    - ✓Repeat endoscopic treatment may be necessary for successful outcomes.
  - Surgeons may perform a dilation, vesicourethral incision, or transurethral resection for post-prostatectomy vesicourethral anastomotic stenosis. (VUAS) (Conditional Recommendation; Evidence Level: Grade C)
    - ✓Repeat endoscopic treatment may be necessary for successful treatment

- Surgeons may perform robotic or open reconstruction for recalcitrant stenosis of the bladder neck or post-prostatectomy vesicourethral anastomotic stenosis. (Conditional Recommendation; Evidence Level: Grade C)

  ✓Reconstruction is challenging and may cause significant urinary incontinence requiring subsequent artificial urinary sphincter implantation.

Management for Urethral Strictures

Summary of evidence	LE
For non-obliterative vesico-urethral anastomotic stricture (VUAS) and radiation-induced bulbomembranous strictures(BMS), **visually controlled dilatation** and **DVIU** yield a patency rate of respectively 0-89% and 25-100% with a low complication rate. It can be performed under loco-regional anesthesia.	3
During DVIU, deep incision might provoke injury to the rectum at the 6 o' clock position and might provoke uro-symphyseal fistulation at the 12 o'clock position.	3
For bladder neck stenosis (BNS), TUR and "hot-knife" incision yield a patency rate of respectively 58.3 and 72% with a low complication rate.	3
Repeat endoluminal treatments in non-obliterative VUAS, radiation-induced BMS or BNS can stabilize the posterior stenosis and are easy to perform compared to reconstructive surgery.	3
Any form of endoluminal treatment might be associated with *de novo* UI (~25%) or worsening of existing UI (~ 15%).	3
VUAS, BMS and BNS with complete obliteration are not included in present series and endoluminal treatment is unlikely to be successful.	3
Urethral stents at the posterior urethra have a rather low patency rate (47-60%) and incontinence rate (19-82%).	3

Management for Urethral Strictures

Recommendations	Strength rating
Perform **visually controlled dilatation** or **DVIU** as 1st line-treatment for a non-obliterative VUAS or radiation-induced BMS.	Weak
Do not perform deep incisions at the **6 and 12 o' clock** position during DVIU for VUAS or radiation-induced BMS.	**Strong**
Perform transurethral resection or "hot-knife" DVIU as 1st line-treatment for patients with non-obliterative BNS after surgery for benign prostatic obstruction.	**Strong**
Perform repeat endoluminal treatments in non-obliterative VUAS or BNS in an attempt to stabilize the stricture.	Weak
Warn patients about the risk of *de novo* urinary incontinence (UI) or exacerbation of existing UI after endoluminal treatment.	Weak
Do not perform endoluminal treatment in case of VUAS, BMS and BNS with complete obliteration.	**Strong**
Do not use stents for strictures at the posterior urethra.	Weak

Management for Urethral Strictures

Recommendations	Strength rating
Perform ReDo VUA in non-irradiated patients and irradiated patients with adequate bladder function with obliterative VUAS or VUAS refractory to endoluminal treatment.	Weak
Warn patient that UI is inevitable after transperineal ReDo VUA and that subsequent anti-UI surgery might be needed in a next stage, after at least 3-6 months.	**Strong**
Offer ReDo VUA by retropubic approach if the patient is pre-operatively continent.	Weak

Summary of evidence	LE
ReDo vesico-urethral anastomosis (VUA) has patency rates of 60-91% in non-irradiated patients and 67% in irradiated patients with obliterative VUAS or VUAS refractory to endoluminal treatment.	3
Urinary incontinence is inevitable after transperineal ReDo VUA. Artificial urinary sphincter placement can be offered after 3-6 months if patency of ReDo VUA is ensured.	3
De novo incontinence with retropubic ReDo VUA is 0-58%.	3

Management for Urethral Strictures

Recommendations	Strength rating
Perform bladder neck reconstruction with Y-V or T-plasty for treatment refractory BNS.	Weak
Warn patients about ***de novo*** **urinary incontinence after reconstruction for BNS or BMS** with previous BPO surgery as etiology.	**Strong**

Summary of evidence	LE
Bladder neck reconstruction with Y-V or T-plasty for treatment refractory BNS has patency rates of 83-100%.	3
Incontinence occurs in up to 14% with bladder neck reconstruction and up to 25% after reconstruction of BMS after previous surgery for BPO.	3

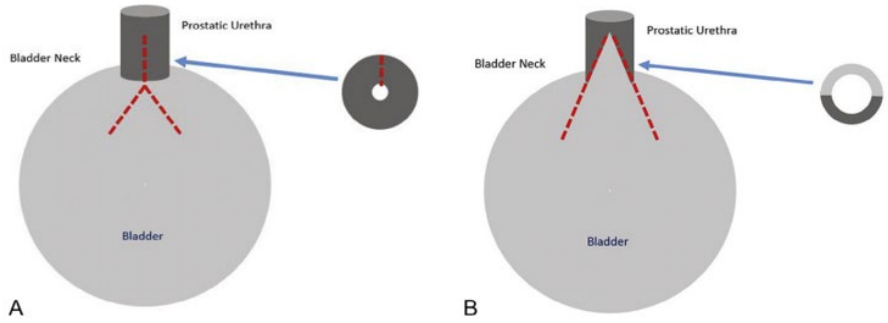

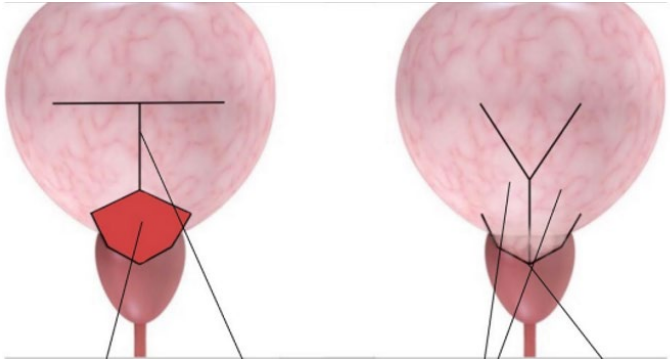

Management for Urethral Strictures

Recommendations [Radiation-induced BMS]	Strength rating
Use either excision and primary anastomosis (EPA) or augmentation urethroplasty for short (< 2.5 cm) radiation-induced BMS refractory to endoscopic treatment depending on surgeon's experience.	Weak
Perform augmentation urethroplasty for long (> 2.5 cm) radiation-induced BMS.	Weak
Warn patients about the risk of *de novo* incontinence and new onset erectile dysfunction after **urethroplasty for radiation-induced BMS.**	**Strong**

Summary of evidence [Radiation-induced BMS]	LE
Patency rates of urethroplasty for radiation-induced BMS is 80% with no significant differences between EPA and augmentation urethroplasty.	3
Radiation-induced BMS longer than 2-2.5 cm are rarely amenable for EPA.	3
De novo incontinence and new onset ED after urethral surgery for radiation-induced BMS are reported in respectively 19-26% and 0-35% of cases.	3

Management for Urethral Strictures

Recommendations [pelvic fracture urethral injury]	Strength rating
Do not perform endoscopic treatment for an **obliterative stenosis**.	**Strong**
Perform one attempt at endoluminal treatment for a short, non-obliterative stenosis.	Weak
Do not perform more than two DVIU and/or dilatations for a short and non-obliterative recurrence after EPA for a traumatic posterior stenosis if long-term urethral patency is the desired intent.	Weak

Summary of evidence [pelvic fracture urethral injury]	LE
Endoluminal treatment of obliterative stenoses is not successful and may create false passages towards bladder or rectum.	3
A 1st DVIU has stricture-free rates of 22.9-77.3% for a short and non-obliterative recurrence after EPA.	3
Three or more endoscopic incisions are never successful for recurrence after EPA.	3

- Clinicians should use retrograde urethrography with voiding cystourethrogram and/or retrograde+antegrade cystoscopy for preoperative planning of delayed urethroplasty after pelvic fracture urethral injury. (Moderate Recommendation; Evidence Level: Grade C)

  - ✓The VCUG may include a static cystogram to determine the competency of the bladder neck mechanism and the level of the bladder neck in relation to the symphysis pubis.

  - ✓Other adjunctive studies may include antegrade cystoscopy (with or without fluoroscopy) and pelvic CT or MRI to assess the proximal extent of the injury, degree of malalignment of the urethra, and length of the defect.

- Definitive urethral reconstruction for pelvic fracture urethral injury should be planned only after major injuries stabilize and patients can be safely positioned for urethroplasty. (Expert Opinion)
  - ✓No optimal time to perform urethral reconstruction has been established, with studies reporting a wide range of times from 6 weeks to 4 years.
  - ✓Reconstruction should occur when patient factors allow the surgery to be performed (usually within 3 to 6 months after the trauma).
    - ➢Patient positioning in the lithotomy (standard, high, or exaggerated) may be limited until orthopedic and lower extremity soft tissues injuries have resolved.

Management for Urethral Strictures

Recommendations	Strength rating
Perform open reconstruction for post-traumatic posterior stenosis only in high-volume centres.	Weak
Perform **progressive perineal excision and primary anastomosis (EPA)** for obliterative stenosis.	**Strong**
Perform **progressive perineal EPA** for non-obliterative stenosis after failed endoluminal treatment.	**Strong**
Perform a **midline perineal incision** to gain access to the posterior urethra.	**Strong**

Do not perform **total pubectomy** during abdomino-perineal reconstruction.	**Strong**
Reserve abdomino-perineal reconstruction for complicated situations including very long distraction defect, para-urethral bladder base fistula, trauma-related recto-urethral fistula, and bladder neck injury.	Weak
Perform another urethroplasty after 1st failed urethroplasty in motivated patients not willing to accept palliative endoluminal treatments or urinary diversion.	Weak
Use a local tissue flap to fill up excessive dead space or after correction of a concomitant recto-urethral fistula	Weak

Management for Urethral Strictures

Summary of evidence [Urethroplasty for post-traumatic posterior stenosis]	LE
The best results are obtained after the 1st urethroplasty.	4
The **overall stricture-free rate** after EPA is 85.7%. (By using the progressive perineal approach)	3
After failed endoluminal treatment, **EPA** is the standard treatment for a non-obliterative stenosis.	3
Both a midline and inverted U perineal incision equally gain access to the posterior urethra, but a **midline incision** is associated with less anatomical damage to local vessels and nerves, reduced risk of surgical site infection and hospital stay.	2b
Total pubectomy during transpubic abdomino-perineal reconstruction has a higher complication rate (bleeding, pelvic instability , dead space) compared to partial (superior or inferior) pubectomy with no gain in surgical exposure.	4

By using the progressive perineal approach, a combined transpubic abdomino-perineal approach is usually not needed except for very long distraction defects and in case of complicated situations, which include associated para-urethral bladder base fistula, trauma-related recto-urethral fistula, and bladder neck injury.	3
If the urethra cannot be anastomosed in a tension-free fashion or in case of ischemic narrowing/necrosis of the bulbar urethra, options are a tubed preputial island flap, staged buccal mucosa graft urethroplasty with flap, staged buccal mucosa dartos flap, radial forearm free flap urethroplasty or entero-urethroplasty.	3
In case of excessive dead space after resection of the fibrosis, local flaps have been advised to fill up this space and support the anastomosis. These flaps are also useful to separate the suture lines in case of a concomitant recto-urethral fistula.	3